


Adapted EQUUS-FAP

Equine facial pain assessment in still images

Ears	Both ears turned forwards	0
	At least one ear lateral position or further to backwards	1
	Both ears turned backwards	2
Orbital Tightening	Relaxed	0
	A bit tightening of the eyelids	1
	Obviously tightening of eyelids / eye closed	2
Angulated upper eyelid	Relaxed	0
	A bit more visible	1
	Obviously more visible	2
Visibility of the sclera	Sclera is not visible	0
	An edge of the sclera is visible	1
	Obviously more visible	2
Corners mouth/lips	Relaxed	0
	Lifted a bit	1
	Obviously lifted / strained	2
Nostrils	Relaxed	0
	A bit more opened	1
	Obviously more opened (dilated mediolaterally)	2
Total		/12

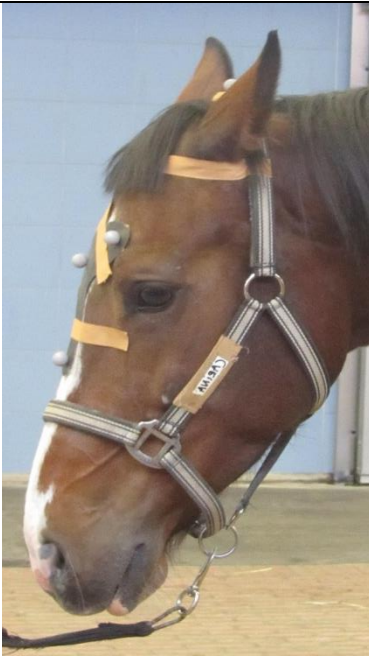Ears



2




2



2



Orbital Tightening



2






2



2



Angulated upper eyelid

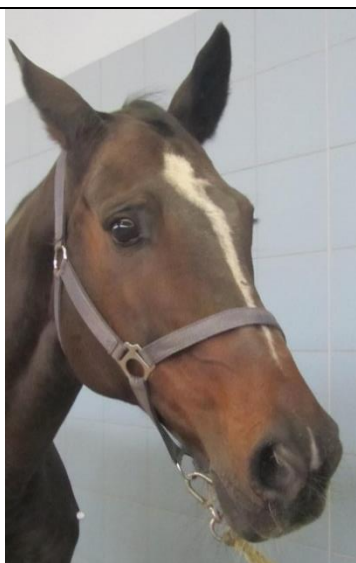0	0	0
		

1	1	1
		


2





2



2



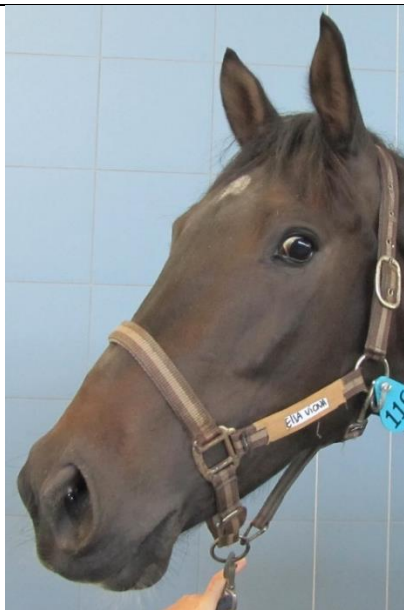Visibility of the sclera



2





2



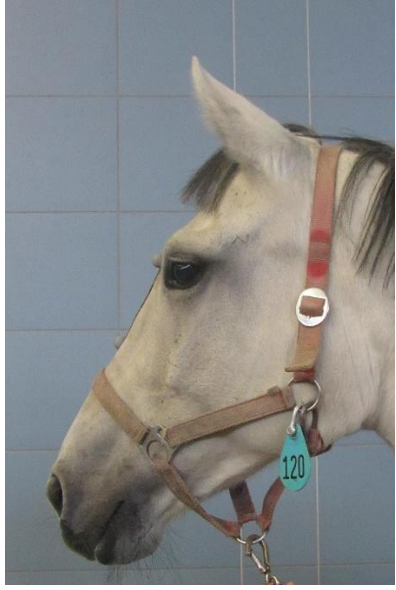2



Corners mouth/lips



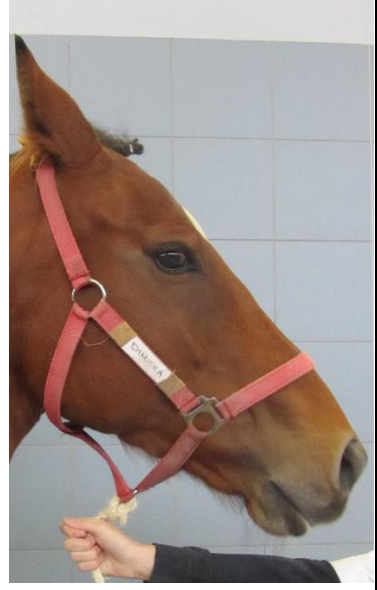2




2



2



Nostrils



2



2



2

